



## Narrative Review

## Unique medical issues in adult patients with mucopolysaccharidoses



John Mitchell <sup>a,\*</sup>, Kenneth I. Berger <sup>b</sup>, Andrea Borgo <sup>c</sup>, Elizabeth A. Braunlin <sup>d</sup>, Barbara K. Burton <sup>e</sup>,  
Kemel A. Ghotme <sup>f</sup>, Susanne G. Kircher <sup>g</sup>, David Molter <sup>h</sup>, Paul J. Orchard <sup>d</sup>, James Palmer <sup>i</sup>, Gregory M. Pastores <sup>j</sup>,  
David M. Rapoport <sup>b</sup>, Raymond Y. Wang <sup>k</sup>, Klane White <sup>l</sup>

<sup>a</sup> Montreal Children's Hospital, Montreal, Quebec, Canada

<sup>b</sup> New York University School of Medicine, New York, NY, United States

<sup>c</sup> Orthopaedics and Traumatology Hospital, Padova, Italia

<sup>d</sup> University of Minnesota, Minneapolis, MN, United States

<sup>e</sup> Lurie Children's Hospital, Chicago, IL, United States

<sup>f</sup> Faculty of Medicine, Universidad de La Sabana, Santa Clara, Chía, Cundinamarca, Colombia, and Neurosurgery Unit, Fundación Santafé de Bogotá, Bogotá, Bogota D.C., Colombia

<sup>g</sup> Medical University of Vienna, Vienna, Austria

<sup>h</sup> St. Louis Children's Hospital, St. Louis, MO, United States

<sup>i</sup> Salford Royal Hospital, Salford, United Kingdom

<sup>j</sup> Mater Misericordiae University Hospital, Ireland

<sup>k</sup> CHOC Children's Specialists, Orange, CA, United States and School of Medicine, University of California-Irvine, Orange, CA, United States

<sup>l</sup> Children's Hospital Seattle, Seattle, WA, United States

## ARTICLE INFO

## Article history:

Received 25 March 2016

Received in revised form 13 May 2016

Accepted 15 May 2016

Available online 11 June 2016

## Keywords:

Mucopolysaccharidoses

Adult

Disease management

Lysosomal storage diseases

Review

Enzyme replacement therapy

## ABSTRACT

The mucopolysaccharidoses are a group of inherited metabolic diseases caused by deficiencies in enzymes involved in the sequential degradation of glycosaminoglycans (GAGs) leading to substrate accumulation in various tissues and organs. GAG accumulation can cause growth retardation and progressive damage to respiratory, cardiovascular, musculoskeletal, nervous, gastrointestinal, auditory, and visual systems. In the past, few people with severe phenotypic mucopolysaccharidosis (MPS) reached adulthood. However, better methods for diagnosis, multi-disciplinary care, and new therapies have extended lifespan, leading to an increasing number of patients surviving beyond childhood. The growing number of adult MPS patients poses significant challenges for clinicians who may not be familiar with the clinical manifestations of MPS. In addition, as new interventions have changed the natural history of these disorders, it is difficult to anticipate both the impact on life expectancy and other complications that may occur as these patients age. Because the MPS disorders are multi-organ diseases, their management requires a coordinated multi-disciplinary approach. Here we discuss the unique pattern of medical issues and multi-organ involvement in adult patients with MPS and identify the challenges that are associated with management of MPS. This review is based on information from an expert investigator meeting with MPS specialists held October 2–4, 2014 in Dublin, Ireland, as well as on current literature searches focusing on MPS and adults.

© 2016 The Authors. Published by Elsevier B.V. on behalf of European Federation of Internal Medicine. This is an open access article under the CC BY-NC-ND license (<http://creativecommons.org/licenses/by-nc-nd/4.0/>).

**Abbreviations:** DAS, Difficult Airway Society; ERT, Enzyme replacement therapy; GAGs, Glycosaminoglycans; HSCT, Hematopoietic stem cell transplantation; MPS, Mucopolysaccharidosis; QoL, Quality of life.

\* Corresponding author at: Montreal Children's Hospital, 1001 Decarie, A04.6309, Montreal, Quebec H4A 3J1, Canada. Tel.: +1 5144124418; fax: +1 5144124329.

E-mail addresses: [john.mitchell@mhuc.mcgill.ca](mailto:john.mitchell@mhuc.mcgill.ca) (J. Mitchell),

[Kenneth.Berger@nyumc.org](mailto:Kenneth.Berger@nyumc.org) (K.I. Berger), [andrea.borgo@sanita.padova.it](mailto:andrea.borgo@sanita.padova.it) (A. Borgo),

[braun002@umn.edu](mailto:braun002@umn.edu) (E.A. Braunlin), [bburton@luriechildrens.org](mailto:bburton@luriechildrens.org) (B.K. Burton),

[Kemel11@yahoo.com](mailto:Kemel11@yahoo.com) (K.A. Ghotme), [susanne.kircher@meduniwien.ac.at](mailto:susanne.kircher@meduniwien.ac.at) (S.G. Kircher),

[molterd@ent.wustli.edu](mailto:molterd@ent.wustli.edu) (D. Molter), [orcha001@umn.edu](mailto:orcha001@umn.edu) (P.J. Orchard),

[james.palmer@srft.nhs.uk](mailto:james.palmer@srft.nhs.uk) (J. Palmer), [gpastores@mater.ie](mailto:gpastores@mater.ie) (G.M. Pastores),

[david.rapoport@mssm.edu](mailto:david.rapoport@mssm.edu) (D.M. Rapoport), [rawang@CHOC.org](mailto:rawang@CHOC.org) (R.Y. Wang),

[Klane.white@seattlechildrens.org](mailto:Klane.white@seattlechildrens.org) (K. White).

<http://dx.doi.org/10.1016/j.ejim.2016.05.017>

0953-6205/© 2016 The Authors. Published by Elsevier B.V. on behalf of European Federation of Internal Medicine. This is an open access article under the CC BY-NC-ND license (<http://creativecommons.org/licenses/by-nc-nd/4.0/>).

## 1. Introduction

The mucopolysaccharidoses are caused by deficiencies in enzymes involved in the sequential degradation of glycosaminoglycans (GAGs, hydrophilic polymers of highly modified hexose saccharides), which are ubiquitous in connective tissues. The resulting impaired degradation of GAGs in cells and tissues leads to substrate accumulation causing progressive multi-organ dysfunction [1]. Seven types of mucopolysaccharidosis (MPS) disorders have been described (Table 1), with MPS III and MPS IV each having two or more biochemical subtypes [1,2]. MPS I can be subdivided in three subtypes according to severity: Hurler syndrome (most severe), Hurler–Scheie syndrome, and Scheie

**Table 1**

Overview of the mucopolysaccharidoses. Adapted from Muenzer et al, 2011 [1,2], with permission.

	Eponym	Deficient enzyme	Storage material
MPS I	Hurler, Hurler–Scheie, Scheie	$\alpha$ -L-iduronidase	Dermatan sulfate, heparan sulfate
MPS II	Hunter	Iduronate-2-sulfatase	Dermatan sulfate, heparan sulfate
MPS III	Sanfilippo	A: heparan N-sulfatase B: $\alpha$ -N-acetylglucosaminidase C: acetyl-CoA: $\alpha$ -glucosaminide acetyltransferase D: N-acetylglucosamine 6-sulfatase	Heparan sulfate
MPS IV	Morquio	A: N-acetylgalactose 6-sulfatase B: $\beta$ -galactosidase	A: Keratan sulfate, chondroitin sulfate B: Keratan sulfate
MPS VI	Maroteaux–Lamy	Arylsulfatase B	Dermatan sulfate, chondroitin sulfate
MPS VII	Sly	$\beta$ -Glucuronidase	Dermatan sulfate, heparan sulfate, chondroitin sulfate
MPS IX <sup>a</sup>	Hyaluronidase deficiency	Hyaluronidase	Hyaluronan

<sup>a</sup> Described in only four patients to date [2].**Fig. 1.** Typical appearance of adults with severe forms of (left) MPS IVA showing short stature with short trunk and neck, profound skeletal and joint abnormalities and (middle) MPS VI showing short stature, broad or thickened facial features, and small hands showing some clawing. Right: patient with a non-classical phenotype of MPS IVA showing normal stature (reproduced from Hendriksz et al. [6], with permission).

syndrome (least severe). There are also neurological and non-neurological forms of MPS II.

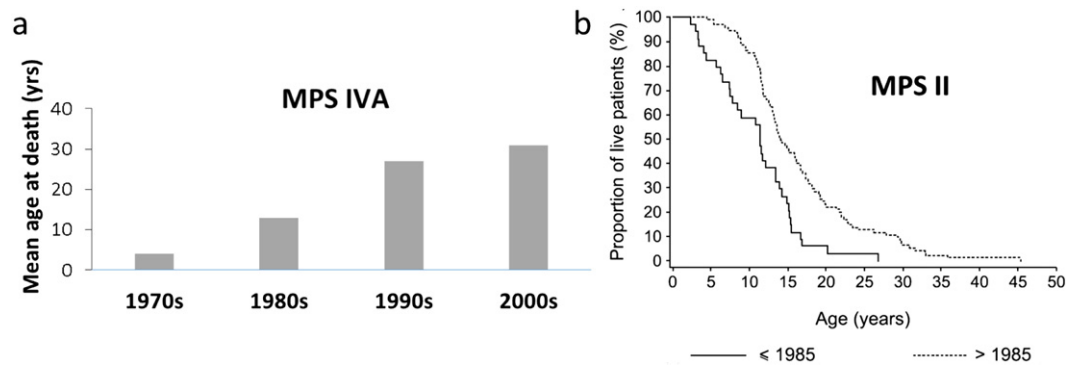
All MPS disorders follow an autosomal recessive inheritance pattern, with the exception of MPS II, which is X-linked. Patients with MPS progressively develop growth impairment and deficiencies in respiratory, cardiovascular, musculoskeletal, nervous, gastrointestinal, auditory,

and visual systems (Fig. 1, Table 2). Patients with MPS I, II, III, and VII may also exhibit learning difficulties and neurological decline [1]. Although MPS IV and VI are generally considered not to affect neurocognitive development, some patients may have an IQ below the normal range [3,4]. It remains to be elucidated if this is a direct result of the disease or indirectly results from reduced school attendance or

**Table 2**

Clinical manifestations and medical issues of the mucopolysaccharidoses and adult specialists who may be involved in the evaluation and/or management care of these manifestations [1,7–14].

Common clinical manifestations and medical issues	MPS types	Adult specialist
Musculoskeletal manifestations: deformities of the spine, thoracic cage, hips, knees, skull, and/or hands, short stature, joint abnormalities, joint pain, joint restriction/hypermobility	All types	Orthopedist, rheumatologist, physiotherapist
Spinal cord issues: spinal instability, cord compression, myelopathy	I, II, IV, VI	Neurologist, spine orthopedist, neurosurgeon, anesthesiologist
Ear, nose, throat manifestations, speech problems	All types	Otolaryngologist, speech therapist
Respiratory manifestations: upper and/or lower airway obstruction, restrictive disease, sleep-disordered breathing	All types	Otolaryngologist, pulmonologist, spine orthopedist
Cardiac manifestations: aortic and mitral valve insufficiency / stenosis, left ventricular hypertrophy, abnormal diastolic function, pulmonary hypertension	All types	Cardiologist, intensivist, anesthesiologist
Ocular manifestations: corneal clouding, refractive errors, glaucoma, papilledema	All types	Ophthalmologist
Cognitive decline, loss of motor function, behavioral problems, epilepsy	I (mainly Hurler, Hurler–Scheie), severe II, III, VII	Neurologist, psychiatrist, neuropsychologist
Abdominal manifestations: hepatomegaly, splenomegaly, umbilical/inguinal hernias, chronic diarrhea	All types	Gastroenterologist, general surgeon
Papular pearly rash across the scapulae, dermal melanocytosis, hirsutism	II, III, VI	Dermatologist
Carpal tunnel syndrome	I, II, VI	Neurologist, hand surgeon
Dental abnormalities: widely spaced and/or abnormally shaped teeth, weak enamel, gingival hyperplasia	I, II, IV, VI, VII	Dentist
Frequent surgery, diagnostic procedures requiring anesthesia	All types	Anesthesiologist
Follow-up of late effects/complications related to hematopoietic stem cell transplantation	Mainly MPS I–Hurler	Bone marrow transplant specialist
Reduced quality of life, depressed feelings	All types	Psychologist, psychiatrist
Coordination of care	All types	Clinical geneticist, metabolic physician, general physician



**Fig. 2.** Mean age of death is increasing in several MPS types: (a) Mean age at death over time between 1975 and 2010 in patients with MPS IVA A (N = 27). Reproduced from Lavery and Hendriks [17], with permission from Springer. (b) Survival curves for 129 MPS II patients from the Hunter Outcome Survey according to the time period in which they died (in or before 1985 (N = 34) or after 1985 (N = 95)). Reproduced from Jones et al [15], with permission from Springer.

educational stimulation. All MPS disorders are heterogeneous with respect to genotype, clinical presentation, and progression rate, representing a disease continuum from slow or attenuated to rapid disease progression. Patients with rapidly progressing MPS experience symptoms in a wide range of organ systems and clinical recognition is therefore early; patients with attenuated forms and less obvious clinical manifestations may not be diagnosed until they reach adolescence or adulthood [5].

Individuals with MPS, particularly those with rapidly progressing variants, have historically experienced a shortened lifespan, with many dying during childhood or adolescence. As a result, adults once represented a very small percentage of the MPS population consisting mainly of those with a more slowly progressing disease phenotype. However, studies in MPS II and MPS VI patients show a trend towards longer survival over recent decades (1990s–2010s) (Fig. 2) [15,16]. Several factors may explain this trend, including improved early diagnosis, earlier recognition of patients with slower disease progression, advances in supportive, multi-disciplinary care, increased awareness of disease manifestations and anesthetic risks, and the introduction of effective systemic therapies including enzyme replacement therapy (ERT) and hematopoietic stem cell transplantation (HSCT). It can be expected that the current trend towards longer survival will continue and that MPS will become an important chronic adult medical issue.

Despite increased interest in rare diseases among clinicians and researchers, published literature on adults with MPS remains limited. Although several studies in large groups of MPS patients exist [7,9,10,18–22], adults make up only a small portion of these study populations. This review discusses the unique medical issues of adults with MPS based on information from presentations and discussions among 53 participants (including pediatric subspecialists, medical geneticists, adult MPS specialists, nurses, and patients) who met on October 2–4, 2014, in Dublin, Ireland, and on additional relevant literature selected by the specialists and a search in PubMed using search terms “(mucopolysaccharidoses[MeSH Terms]) AND (adult OR age)” performed in January 2015 with filter “English and humans” (1078 results). This review focuses on patients with intact cognition. It should be noted that cognitive impairment can greatly affect clinical care and outcomes of therapies discussed in this review.

## 2. Multi-disciplinary management

MPS disorders are multi-organ diseases that require multi-disciplinary management involving clinical geneticists, metabolic physicians, orthopedists, general surgeons, neurosurgeons, pulmonologists, cardiologists, neurologists, anesthesiologists, otolaryngologists, ophthalmologists, dentists, transplant physicians, psychiatrists, and

physiotherapists (Table 2). The management of MPS in an adult clinical setting creates challenges due to the patients' short stature and medical complexity, the fact that most internists are unfamiliar with MPS disorders, and the limited availability of assistance for multi-disciplinary patient care (coordination of timely, patient-friendly, integrated care by different specialists) in adult clinics. Internists should be aware of the special needs of MPS patients. A proper program is required to guide young adults with MPS from pediatric to adult health care systems, ensuring routine review and preserving of important clinical information and experiences [23,24]. A coordinating physician (generally a clinical geneticist, metabolic physician, or general physician) can help streamline adult care by organizing a multi-disciplinary team of adult specialists around the patient. This entails proper training and commitment of specialists to the evaluation and care of MPS patients. The coordinating physician should ensure the patient's autonomy and self-determination prevail in decision making and barriers to care and issues arising from the patient's health-related quality of life (QoL), independence, and daily functioning are properly addressed.

## 3. Systemic therapies

MPS-specific therapies include ERT and HSCT. In the past decade, the use of recombinant human ERT has become a widely available treatment for MPS I, II, IVA, and VI. Clinical trials of ERT for MPSVII and MPS IIIA are ongoing [25,26]. ERT has been shown to have favorable effects on urinary GAG levels, endurance, respiratory function, range of joint motion, hepatomegaly, growth (height), and cardiac function [27–31]. In addition, one study recently suggested a significant survival benefit in MPS VI patients treated with ERT over ERT-naïve patients [16].

HSCT is considered the standard of care in infants with severe MPS I (Hurler syndrome or MPS IH), positively affecting cognitive and intellectual development [7]. A clear survival benefit has been shown for patients with MPS IH treated with HSCT [32]. HSCT is preferably done as early as possible after birth, as the long-term neurocognitive prognosis after HSCT is predominantly determined by the degree of damage to the central nervous system at the time of transplant [33]. Although some case reports have also shown favorable outcomes in other types of MPS [34–36], HSCT is primarily reserved for MPS IH (associated with neurocognitive impairment) due to the inability of intravenously infused ERT to pass the blood–brain barrier. More research is warranted to evaluate whether the long-term advantages of HSCT outweigh its significant morbidity risks in other types of MPS [37].

HSCT and ERT are most effective when started early in life, before the development of irreversible damage [1,7]. Limited data exist on the effects of ERT when started in adulthood and more research is warranted to fill this evidence gap.

**Table 3**

Overview of musculoskeletal manifestations in the mucopolysaccharidoses. Reprinted from J Pediatr Rehabil Med, Volume 3, White KK and Harmatz P, Orthopedic management of mucopolysaccharide disease, Pages 47–56, 2010, with permission from IOS Press [13].

	Cervical stenosis	Cervical instability	Thoracolumbar kyphosis	Scoliosis	Hip dysplasia	Genu valgum	Carpal tunnel syndrome
MPS I (severe)	2+	1+	3+	2+	3+	2+	2+
MPS I (attenuated)	2+	0	0	0	0	0	3+
MPS II	1+	0	1+	1+	1+	0	2+
MPS III	0	0	0	1+	2+	1+	0
MPS IV	2+	3+	2+	0*	3+	3+	0
MPS VI	3+	3+	1+	0	2+	0	1+

0 = not reported; 1 = rare; 2 = common; 3 = frequent.

\* Kyphoscoliosis is frequently observed in patients with MPS IVA [10].

#### 4. Musculoskeletal manifestations

Skeletal and joint abnormalities are observed in all MPS types [8,10,13,38,39]. Each disorder is associated with typical radiological findings (dysostosis multiplex) [40]; however, great phenotypic variability exists among affected individuals (Table 3). Adult patients with severe forms of MPS I, II, IV, VI, and VII generally show significant bone and joint deformities and short stature. Degenerative joint disease and subluxation, especially of the hip joints, lumbosacral kyphosis, and genu valgum worsen with age during childhood and, to a lesser degree, adolescence. Bone dysplasia, which can be worsened by the abnormality of the joint in case of subluxation or severe valgus, can ultimately lead to painful arthritis and severe functional impairment requiring the use of a walking aid or wheelchair. Studies have shown little effect of ERT and HSCT on bone disease [33,41].

Joint pain is a common manifestation of most MPS disorders, particularly those with severe skeletal involvement. In a study including 36 children and 27 adults with MPS IVA, 74% of adult patients experienced joint pain (versus 64% of children), most frequently in the lower extremities [42]. Most adults (85.2%) were using a wheelchair at least some of the time. Those adults who only required a wheelchair “when needed” experienced more intense and widespread pain due to increased mechanical joint stress associated with ambulation than adults requiring a wheelchair all the time [42].

Several guidelines for monitoring and managing musculoskeletal manifestations of MPS have been published [13,43–45]. These recommend assessment of the hips, lower extremities, spine, and upper limb function at diagnosis and on a regular basis (e.g. MPS II, MPS IVA) [6,43,45] or when clinically indicated thereafter (e.g. MPS VI) [46]. It is important that these evaluations are continued through adulthood. In some cases, hip dysplasia can be treated by pelvic and femoral osteotomy or shelf acetabuloplasty. Adult patients with severe genu valgum may benefit from osteotomy [43]. However, long-term inflammatory changes and the progressive nature of MPS tend to limit the long-term benefits of these procedures [47]. Nevertheless, they may give patients additional years of activity, comfort, and improved QoL.

In case of severe arthritis, joint replacement can be considered [43,48,49]. The limited activity levels of adults with MPS are favorable for the longevity of prosthetics. However, hip or knee replacement in these patients is not straightforward and is associated with a high risk of complications due to short stature and abnormally shaped bones, often requiring modular or custom implants, and due to previous

surgical procedures leading to less viable tissue and more scar tissue [43]. Allograft augmentation is often required and may complicate surgery. Long-term benefits of hip and knee replacements in MPS patients have not been described in the literature. Potential alternatives to surgery include physical therapy and rehabilitation, use of a cane or walker, pain-relieving medications, or glucocorticoid (steroid) injections into painful, inflamed, joints. Weight loss/control can be helpful in patients who are overweight, which is more frequent in the MPS population. The average body mass index of MPS patients tends to be slightly above Centers for Disease Control and Prevention reference curves, although still within the normal range (around 25 for MPS IVA and around 23 for MPS VI adults) [30,38,50]. There is no clinical evidence that supports the use of bracing in adult MPS patients [49].

Because of the high surgical (anesthetic) risk (see [Respiratory manifestations](#) and [Anesthesia](#) below), and uncertain long-term benefits in adults with MPS, the experts at the meeting in Dublin recommended surgery only when pain limits everyday activities, when patients experience pain with rest, when joint stiffness limits motion, or when anti-inflammatory drugs, physical therapy, or walking support provide inadequate pain relief. The patient's QoL should always be balanced against the risks of surgery/anesthesia for each case individually. As mobility loss can negatively impact QoL [42], the patient's potential to remain mobile should always be considered in the decision to operate. When surgery is indicated, it is important to have a surgical group familiar with the specific surgical and anesthetic issues associated with MPS.

#### 5. Respiratory manifestations

Respiratory impairments, including obstructive and restrictive disease, occur in all MPS types and are among the most important causes of mortality [15,17]. The potential underlying causes of these respiratory manifestations are diverse (Table 4) [11,12]. Sleep-disordered breathing, i.e. obstructive sleep apnea or sustained hypoventilation, is often the first sign of respiratory compromise [51,52]. In the long term, sleep-disordered breathing can have cardiac consequences, including pulmonary hypertension, cor pulmonale, and cardiorespiratory failure [44]. Pulmonary impairment and sleep-disordered breathing both lead to debilitating fatigue, an often underreported manifestation of MPS. In a study in patients with MPS IVA, 63% of adults (N = 27) reported fatigue [42].

**Table 4**

Potential underlying causes of respiratory problems in patients with MPS. Adapted from Berger et al [12], with permission.

Airway obstruction	Restrictive disease	Other mechanisms
Narrowing of supraglottic and infraglottic airway due to	Progressive reduction of lung volume due to	• Disproportional length of trachea and spine • Spinal cord compression • Cardiac disease • Central nervous system disease • Hydrocephalus
• GAG deposition and secondary inflammation; • skull/spine abnormalities; • abnormalities of trachea and main stem bronchi.	• small thoracic cage; • thoracic cage deformities, kyphoscoliosis; • weakness of the diaphragm; • impaired diaphragm motility from enlarged liver/spleen.	



There is a striking lack of publications addressing airway management in adults with MPS but the guidelines for the evaluation and management of respiratory problems and sleep-disordered breathing in MPS patients, published in 2013, apply for both pediatric and adult patients [12]. It is important that adult pulmonologists are aware of the high respiratory risk associated with MPS. If not properly evaluated, respiratory problems may go unnoticed due to respiratory dysfunction being masked by physical inactivity.

Evaluation of respiratory function in MPS patients can be problematic [12]. Standard values for spirometry cannot be used in patients with short stature and pediatric-size equipment often has to be used. Certain pulmonary function tests may not be possible due to cognitive impairment or behavioral problems. Treatment is as for other forms of obstructive and restrictive pulmonary diseases and is primarily symptomatic.

For the diagnosis of sleep-disordered breathing, guidelines recommend polysomnography in all patients following a diagnosis of MPS, then repeated monitoring based on presence of snoring, excessive daytime somnolence, development of respiratory failure, and a reduction in vital capacity [12]. Sleep-disordered breathing in adult MPS patients can be managed with continuous positive airway pressure (for obstructive sleep apnea) or non-invasive ventilatory support systems (e.g., bi-level positive airway pressure, in case of nocturnal hypoventilation) [12]. New therapies such as oral appliances (e.g. a custom-fitted mouthpiece) may also be considered for obstructive sleep apnea without hypoventilation. Although adenoidectomy and/or tonsillectomy are often performed (particularly in children) [53], there is currently a lack of conclusive evidence of benefit from published post-operative results. These interventions may be only partially successful due to abnormal surrounding tissues. Patients may also benefit from reduction of the tongue (orthognathic surgery), but this has not been described so far.

Tracheostomy should only be considered when other therapies have failed and deferred until absolutely needed. Although immediately life-saving, it is considered an indicator of rapid deterioration and increasing mortality. Tracheostomy is associated with a high risk of complications, such as tracheitis, mucous plug obstruction, or accidental decannulation, and can interfere considerably with activities of daily living, such as working, shopping, and traveling, and requires regular tracheostomy care, suctioning, inhaled medications and other related supplies [12]. However, when indicated, proper training and support can help to maintain or increase the patient's QoL. In particular, preservation of speech and the ability to eat has been shown to be important.

## 6. Ear, nose, and throat manifestations

MPS patients frequently develop progressive hearing loss due to chronic otitis media [54,55]. Whereas young children experience conductive hearing loss, adolescent and adult patients tend to develop mixed hearing loss or pure sensorineural hearing loss [56]. Although pressure equalization tubes (grommets) are often used in MPS patients with otitis media, hearing loss is usually not resolved. Hearing aids (behind the ear, bone anchored, or traditional bone hearing aids) may improve hearing. A case review of the first cochlear implants in two MPS children with profound sensorineural hearing loss recently reported benefit in terms of auditory performance and speech perception [57]. The advantages of this procedure should be balanced against anesthetic risks and the prohibition of magnetic resonance imaging use in patients with cochlear implants. Nerve compression from GAG storage at the internal auditory canal can reduce the efficacy of cochlear implants.

Oral manifestations in MPS patients include gingival hyperplasia, macroglossia, swelling of adenoids and/or tonsils, and impaired opening of the mouth [54]. Mechanical extrinsic compression, intrinsic factors (GAG deposits in the tongue and possibly the esophagus), abnormal nerve function, and/or cognitive issues, can lead to swallowing problems. Hearing impairment and mechanical alterations to the larynx

commonly cause speech problems [14,58]. Poor communication due to hearing and speech problems can lead to depression, isolation, and less participation in care.

## 7. Cardiac manifestations

Cardiac abnormalities are a major cause of mortality in untreated MPS patients [15,17,19]. Several studies have described the cardiac manifestations of MPS, with some providing combined information on both adults and children [59–62]. Cardiac manifestations occur in most adults with MPS I, II, and VI [8,18,38] but have also been described for other types of MPS [63,64]. Progressive aortic and mitral valve insufficiency and stenosis, left ventricular hypertrophy, and abnormal diastolic function are most common [65,66]. Patients with dermatan sulfate GAG accumulation (MPS I, II, VI) have the highest incidence of valve abnormalities [59]. MPS individuals with slowly progressing disease may have severe cardiac valve pathology with few other expressions of the disease [67]. Studies have reported cardiac valve abnormalities in the majority of adult patients with slowly progressing MPS I (Scheie syndrome) [18,68] and in all adult patients with slowly progressing MPS VI [67,69].

Less common cardiac manifestations in adult MPS patients are conduction problems (arrhythmia, complete heart block), left ventricular aneurysms, cardiomyopathy, and coronary artery disease [70–74]. Although cardiac manifestations have only been reported occasionally for MPS III [75], severe life-threatening cardiac problems may occur in these patients as well [70]. Evidence suggests pan-arterial storage of GAGs in all MPS types, as confirmed by an increase in carotid intima-media thickness and arterial dysfunction (increased aortic stiffness, poor endothelial function) versus healthy controls [8,76–79]. Because of this phenomenon, which manifests in childhood and, in untreated individuals, worsens with age, MPS patients tend to exhibit an arterial age comparable to that of healthy subjects three times their age and frequently present with increased blood pressure [8,74,78,80]. In patients with short stature, blood pressure is often difficult to measure accurately in adult clinics.

The presentation, evaluation, and management of cardiac manifestations in MPS disorders have been discussed in detail in 2011 [65]. ERT generally does not improve cardiac valve disease, although it may attenuate or delay valve disease progression. ERT may, however, have a positive impact on left ventricular hypertrophy [66] and ventricular function [81]. HSCT in MPS IH patients does not reverse valve disease but may attenuate progression and preserve ventricular function [82]. Although there is variation between and within MPS types and types of intervention, the existing literature suggests that the maximal impact of ERT and HSCT on cardiac valves may decrease as patients age [31].

Successful valve replacement surgery has been reported in adults with all MPS types except MPS III [65]. Complications may occur during cardiothoracic surgery apart from associated anesthetic risks (discussed below). Thick, small, fibrotic valve annuli can complicate native valve removal, thus prolonging cardiopulmonary bypass time [83]. Myocardial preservation may be difficult in hypertrophied ventricles and GAG-laden coronary vessels. Rehabilitation may be difficult in the presence of orthopedic issues. Successful trans-catheter aortic valve replacement has been reported in a 30 year old with MPS I and may alleviate many major surgical issues [84], but the relatively shortened lifespan of such bioprosthetic valves may limit their usefulness in young adults. Cardiomyopathy is an uncommon finding in adult MPS, although cardiac transplantation has been performed in two individuals [85,86]. Despite the known involvement of the coronary arteries in MPS, coronary artery bypass in an adult has only been reported once [87]. Myocardial infarction has been occasionally described at post mortem examination in untreated MPS adults [88] and twice in adults who had recently begun ERT [73,89].

## 8. Spinal cord manifestations

Spinal instability and cord compression are common in MPS patients (Tables 2, 3). Spinal cord compression may occur at the cranio-cervical junction, the subaxial cervical spine, and the thoracic or lumbar spine [90,91]. It can be due to spinal canal stenosis caused by small, thickened posterior elements, odontoid hypoplasia, thickening of soft elements (dura, ligamentum flavum, cruciate ligaments), disc bulging, deformities such as kyphosis or scoliosis, or a combination of these factors. MPS IVA patients are most prone to atlantoaxial instability, due to a combination of dens hypoplasia and ligamentous laxity [44,92]. Studies focusing on spinal cord compression in adult patients are limited [69,93]. The MorCAP natural history study reported cervical myelopathy or cord compression in 55% of MPS IVA patients > 18 years [10]. In a case series describing nine untreated MPS VI patients aged 19–29 years, spinal cord compression was present in three patients [69]. In a study including 16 children and 15 adults with MPS VI, patients with slowly progressing disease mostly required first cranio-cervical decompression surgery during adolescence or adulthood (median age 24 years); patients with rapidly progressing disease had first surgery at a median age of 12 years [94].

Guidelines for the evaluation and management of spinal cord compression in patients with MPS VI and IVA were published in 2012 and 2013, respectively [90,91]. Recently, a group of experts also published consensus recommendations for the early identification and management of spinal cord compression in MPS IVA patients, including a list of routine and preoperative assessments [92]. Most of the recommendations are applicable to both pediatric and adult MPS patients.

Adult neurosurgeons and spine orthopedists often have little or no training in spinal issues in MPS patients. An internet-based anonymous survey among 20 pediatric and adult neurosurgeons and spine orthopedic surgeons practicing in different countries showed that only one of the six adult specialists who completed the questionnaire reported having experience with MPS patients. Thirty percent of the 20 specialists indicated that they had treated MPS patients aged ≥ 18 years. In 40% of these cases, this concerned a re-intervention from procedures performed at a younger age, underscoring the high risk of recurrence in these patients. Most respondents indicated that care by an interdisciplinary team (at a center of excellence) with participation of pediatric and adult specialists with experience in metabolic disorders and spinal cord issues would be the best approach to manage MPS patients with spinal cord issues.

## 9. Ocular manifestations

Ocular manifestations occur in all MPS types but are most prevalent in MPS I, VI, and VII [95–97]. Progressive corneal clouding and refractive error problems are most common with glaucoma, retinopathy, increased intraocular pressure, optic disc swelling, and optic atrophy also being described. Ocular manifestations can lead to visual impairment, visual field constriction, night blindness, or photosensitivity [95, 96,98]. As vision loss can considerably affect patients' independence and QoL, managing ocular manifestations is important. An overview of ocular manifestations in MPS patients and recommendations for evaluation and management were published in 2010 [96]. Fahnehjelm et al. (2012) published guidelines for the diagnosis and management of ocular manifestations in children with MPS [97] and most also apply to adults. These guidelines recommend assessment of ophthalmological function at diagnosis. Routine follow-up by an ophthalmologist is not recommended for adults [97]. However, a regular basic evaluation of vision and ophthalmological abnormalities is recommended as part of the general routine physical examination [6].

## 10. Anesthesia

MPS patients frequently require general anesthesia for diagnostic imaging and surgical procedures (correction of spinal deformities,

acetabular hip dysplasia or genu valgum, corneal transplant, myringotomy with placement of pressure equalization tubes, spinal decompression surgery, tonsillectomy, adenoidectomy, hernia repair) [27, 99]. Longer life expectancy may lead to an increase in the number of surgical re-interventions, a trend which is already evident today. In the Hunter Outcome Survey, the median number of surgical procedures per patient increased from two in those who died before 1985 to five in those who died since 1985 [15].

Potential anesthetic problems are numerous and encompass not only the surgical procedure itself but also sedation that may be required for preoperative investigations. Abnormal anatomical features and tissue deposits can lead to airway, cardiac, intravenous access, and cervical spine problems. Typical airway complications that can arise during anesthesia include difficulties with bag mask ventilation, intubation/extubation problems, subglottic stenosis, and profuse and thick secretions [100]. Spinal cord compression or atlantoaxial instability also increase anesthetic difficulty; the former because of the increased risk of potential spinal cord ischemia during hypotensive episodes during surgery and the latter from the risk to the cervical spinal cord during airway management. Cardiac problems such as pulmonary hypertension, cardiomyopathy, and valvular disorders are compounded by difficulties in accurately assessing cardiorespiratory reserve [100]. Kyphoscoliosis may interfere with correct positioning during surgery. Behavioral and communication problems as well as neurocognitive delay can hinder assessment of involvement of other organ systems and the management of induction.

The management of adults with MPS is challenging for adult anesthesiologists as the patients' short stature means that pediatric equipment is often required. The variable nature of MPS implies that no two patients present with identical problems; what works for one patient may not work for another. As risk factors such as airway difficulties worsen with age [101], previously successful anesthesia does not guarantee success with future re-interventions. For most adult anesthesiologists, MPS cases are extremely rare; therefore, more time is needed for preoperative assessment and planning. Although past anesthetic charts can identify potential problems and solutions, a metabolic physician or clinical geneticist may be a better important source of information about exercise tolerance, the results of sleep studies and cardiac investigations. Anesthetic risk factors in MPS disorders and recommendations for presurgical planning and pre-, peri-, and postsurgical management have been discussed in detail [100,102]. Potential risks and benefits of procedures should always be discussed with the patient before surgery, including the possibility of emergency tracheostomy as a life-saving measure. Because of the high risk of difficult intubation, paralysis and death, anesthesia in MPS patients should only be planned in tertiary care hospitals that have the expertise to manage anticipated problems.

The results of a survey of the 1900 Difficult Airway Society members (UK) presented by Dr. James Palmer during the Dublin expert meeting summarized the limited experience of anesthesiologists in treating adults with MPS and the high anesthetic risk in these patients. The survey was worded so that clinicians who had no experience with MPS exited the survey immediately. Of the 242 respondents who had any experience with MPS, only 34 (14%) had experience of adult MPS patients, and of these, 30 had anesthetized adult MPS patients in the past year. Just over half had treated four cases or more, mostly patients with MPS IV or VI. Twelve patients received general anesthesia and five regional anesthesia (four with sedation). Minor airway or other problems were reported in four patients, one patient had significant airway difficulty requiring prolonged non-surgical intervention, and seven had major airway problems requiring emergency tracheostomy. Two patients died. These results emphasize the necessity to include anesthesiologists in the multi-disciplinary team of adult specialists in order to ensure that the available knowledge about the patient is accessible to the whole team. In this way, a group of specialists who are familiar with the unique issues of MPS patients during surgery will be involved in the care of these patients and help ensure safe surgical outcomes.

## 11. Other manifestations of MPS

Abdominal region complications including hepatomegaly, splenomegaly, and umbilical or inguinal hernias have been described in all MPS types [7–10]. Although hernias can be surgically repaired, they often recur [6].

Carpal tunnel syndrome or trigger fingers frequently occur in MPS I, II, and VI [13,103,104]. Whereas splinting and non-steroidal anti-inflammatory drugs may be considered for symptomatic treatment of mild cases of carpal tunnel syndrome, surgery (median nerve release) is indicated in cases with clinical and electrodiagnostic evidence of compressive neuropathy [103]. The risk of recurrent carpal tunnel syndrome after surgery in MPS patients has not been defined as yet.

Dental abnormalities (widely spaced teeth with structurally weak enamel, small pointed cusps, spade-shaped incisors, pitted buccal surfaces, gingival hyperplasia) have been described for MPS IVA and MPS VI but appear to be less common in other types of MPS [44,105]. Fluoride supplementation can help to prevent caries. Fissure sealing of dentition may be considered in some cases [6]. Dermatological problems occur in MPS II, MPS III, and MPS VI [1,8,20,106] (Table 2).

## 12. Conclusions

Historically, patients with MPS have primarily been cared for by pediatric specialties. However, with more effective therapy and supportive care, there is an evolution towards an increasing population of MPS patients that will require chronic care as adults. This will create new challenges for adult primary care providers and specialists treating these individuals. It is expected that the number of MPS adults, as well as the likelihood of encountering such patients in an adult specialist's practice, will further increase in the coming years. To provide optimal care, it will be critical to continue routine evaluations of the clinical manifestations of MPS throughout adulthood. Surgical procedures in adult MPS patients may be complicated by several factors, including short stature, bone deformities, obstructive and restrictive airway problems, and increased anesthetic risk. Thus, an individualized approach that balances benefits and risks of surgical procedures is required. To improve the management of MPS in adulthood, the modified natural history of these disorders should be systematically captured, and more clinical studies should include, and focus on, adult patients. There is also a need for programs guiding transition from pediatric to adult health care and for a medical home or coordinating physicians who can monitor disease management and progression. Development of adult rare disease clinics as well as inclusion of treatable rare diseases into training programs in adult medicine may help improve outcomes for adult MPS patients [107]. The importance of management teams composed of health care specialists who are properly trained to meet the specific, unique, medical needs of MPS patients should be stressed.

## Learning points

- The MPS disorders are caused by deficiencies in enzymes involved in GAG catabolism, leading to growth retardation and progressive damage to respiratory, cardiovascular, musculoskeletal, nervous, gastrointestinal, auditory, and visual systems.
- Better methods for diagnosis, multi-disciplinary care, and new therapies have extended lifespan, leading to an increasing number of adults with MPS.
- Optimal care for adults with MPS requires:
  - o Programs guiding transition from pediatric to adult health care
  - o Continuation of routine evaluations of clinical manifestations throughout adulthood
  - o A medical home or coordinating physicians who can monitor disease progression and streamline disease management

- o Management teams composed of health care specialists properly trained to meet the specific, unique, medical needs of adult MPS patients
- o Development of adult rare disease clinics and inclusion of treatable rare diseases into training programs in adult medicine
- o More studies focusing on adult MPS patients

## Conflicts of interest

The content of this manuscript was based on presentations and discussions during an expert meeting that was coordinated and funded by BioMarin Pharmaceutical Inc.

Dr. Mitchell has participated in BioMarin sponsored clinical trials. He has received travel support and consulting fees from BioMarin. Dr. Berger reports grants and personal fees for consultancy from BioMarin and Genzyme, during the conduct of the study; personal fees for consultancy from Teva, and Vertex outside the submitted work. Dr. Borgo reports personal fees from BioMarin, outside the submitted work. Dr. Braunlin reports personal fees for travel and lodging to participate in the expert meeting about MPS in adults from BioMarin Pharmaceutical Inc. associated with the submitted work; grants and non-financial support from BioMarin Pharmaceutical Inc. and consulting fees to her department from Ultragenyx, outside the submitted work. Dr. Burton reports personal fees and clinical trial support from BioMarin; grants, personal fees, and clinical trial support from Shire; personal fees and clinical trial support from Genzyme; personal fees from ReGenX Bio; and clinical trial support from Alexion, Ultragenyx, and Cytonet, outside the submitted work. Dr. Ghotme has nothing to disclose. Dr. Kircher reports personal fees for a lecture held at the Expert meeting about Adulthood and MPS and travel costs from BioMarin Pharmaceutical Inc., associated with the submitted work. Dr. Molter reports personal fees from BioMarin and grants and personal fees from Shire, outside the submitted work. Dr. Orchard reports grants and personal fees from Genzyme, grants from BioMarin, outside the submitted work. Dr. Palmer has nothing to disclose. Dr. Pastores reports an honorarium from BioMarin, during the conduct of the study and prior recipient of grants for the conduct of clinical trials from BioMarin and Genzyme (Sanofi) for enzyme replacement therapy in the mucopolysaccharidoses. Dr. Rapoport reports support from BioMarin for the Dublin meeting and for past consulting on some of the studies. Dr. Wang reports personal fees from BioMarin Pharmaceutical Inc., during the conduct of the study; personal fees and stock ownership from BioMarin Pharmaceutical Inc., outside the submitted work. Dr. White reports personal fees from BioMarin during the conduct of the study and outside the submitted work.

## Acknowledgments

The authors are grateful to Ismar Healthcare NV for their assistance in writing of the manuscript, which was funded by BioMarin Pharmaceutical Inc. The current review is based on presentations and discussions from an expert meeting on MPS and adulthood that was held October 2–4, 2014 in Dublin, Ireland. This meeting was coordinated and funded by BioMarin Pharmaceutical Inc. The authors would like to thank all specialists who participated in this meeting.

## References

- [1] Muenzer J. Overview of the mucopolysaccharidoses. *Rheumatology (Oxford)* 2011; 50(Suppl. 5):v4–v12.
- [2] Imundo I, Leduc CA, Guha S, et al. A complete deficiency of Hyaluronoglucosaminidase 1 (HYAL1) presenting as familial juvenile idiopathic arthritis. *J Inher Metab Dis* 2011; 34:1013–22.
- [3] Azevedo ACM, Artigalás O, Vedolin L, et al. Brain magnetic resonance imaging findings in patients with mucopolysaccharidosis VI. *J Inher Metab Dis* 2013;36: 357–62.
- [4] Davison JE, Kearney S, Horton J, et al. Intellectual and neurological functioning in Morquio syndrome (MPS IVA). *J Inher Metab Dis* 2013;36:323–8.



- [5] Scarpa M, Buffone E, La Marca P, et al. Difficulties in diagnosing slowly progressive mucopolysaccharidosis VI: a case series. *J Pediatr Rehabil Med* 2010;3:71–5.
- [6] Hendriks CJ, Berger KI, Giugliani R, et al. International guidelines for the management and treatment of Morquio A syndrome. *Am J Med Genet A* 2015;167A:11–25.
- [7] Beck M, Arn P, Giugliani R, et al. The natural history of MPS I: global perspectives from the MPS I Registry. *Genet Med* 2014;16:759–65.
- [8] Wraith JE, Beck M, Giugliani R, et al. Initial report from the Hunter Outcome Survey. *Genet Med* 2008;10:508–16.
- [9] Héron B, Mikaeloff Y, Froissart R, et al. Incidence and natural history of mucopolysaccharidosis type III in France and comparison with United Kingdom and Greece. *Am J Med Genet A* 2011;155A:58–68.
- [10] Harmatz P, Mengel KE, Giugliani R, et al. The Morquio A Clinical Assessment Program: baseline results illustrating progressive, multisystemic clinical impairments in Morquio A subjects. *Mol Genet Metab* 2013;109:54–61.
- [11] Muhlebach MS, Wooten W, Muenzer J. Respiratory manifestations in mucopolysaccharidoses. *Paediatr Respir Rev* 2011;12:133–8.
- [12] Berger KI, Fagondes SC, Giugliani R, et al. Respiratory and sleep disorders in mucopolysaccharidosis. *J Inherit Metab Dis* 2013;36:201–10.
- [13] White KK, Harmatz P. Orthopedic management of mucopolysaccharide disease. *J Pediatr Rehabil Med* 2010;3:47–56.
- [14] Nakarat T, Läßig AK, Lampe C, Keilmann A. Alterations in speech and voice in patients with mucopolysaccharidoses. *Logoped Phoniatr Vocol* 2014;39:30–7.
- [15] Jones SA, Almásy Z, Beck M, et al. Mortality and cause of death in mucopolysaccharidosis type II – a historical review based on data from the Hunter Outcome Survey (HOS). *J Inherit Metab Dis* 2009;32:534–43.
- [16] Giugliani R, Lampe C, Guffon N, et al. Natural history and galsulfase treatment in mucopolysaccharidosis VI (MPS VI, Maroteaux–Lamy syndrome)–10-year follow-up of patients who previously participated in an MPS VI survey study. *Am J Med Genet A* 2014;164A:1953–64.
- [17] Lavery C, Hendriks C. Mortality in patients with Morquio Syndrome A. *JIMD Rep* 2015;15:59–66.
- [18] Thomas JA, Beck M, Clarke JTR, Cox GF. Childhood onset of Scheie syndrome, the attenuated form of mucopolysaccharidosis I. *J Inherit Metab Dis* 2010;33:421–7.
- [19] Young ID, Harper PS, Newcombe RG, Archer IM. A clinical and genetic study of Hunter's syndrome. 2. Differences between the mild and severe forms. *J Med Genet* 1982;19:408–11.
- [20] Schwartz IVD, Ribeiro MG, Mota JG, et al. A clinical study of 77 patients with mucopolysaccharidosis type II. *Acta Paediatr Suppl* 2007;96:63–70.
- [21] Hendriks CJ, Harmatz P, Beck M, et al. Review of clinical presentation and diagnosis of mucopolysaccharidosis IVA. *Mol Genet Metab* 2013;110:54–64.
- [22] Swiedler SJ, Beck M, Bajbouj M, et al. Threshold effect of urinary glycosaminoglycans and the walk test as indicators of disease progression in a survey of subjects with mucopolysaccharidosis VI (Maroteaux–Lamy syndrome). *Am J Med Genet* 2005;134A:144–50.
- [23] Gleeson H, McCartney S, Lidstone V. 'Everybody's business': transition and the role of adult physicians. *Clin Med* 2012;12:561–6.
- [24] Lee PJ. Growing older: the adult metabolic clinic. *J Inherit Metab Dis* 2002;25:252–60.
- [25] Gilkes JA, Heldermon CD. Mucopolysaccharidosis III (Sanfilippo Syndrome)—disease presentation and experimental therapies. *Pediatr Endocrinol Rev* 2014;12(Suppl. 1):133–40.
- [26] Sands MS. Mucopolysaccharidosis type VII: a powerful experimental system and therapeutic challenge. *Pediatr Endocrinol Rev* 2014;12(Suppl. 1):159–65.
- [27] Valayannopoulos V, Wijburg FA. Therapy for the mucopolysaccharidoses. *Rheumatology (Oxford)* 2011;50(Suppl. 5):v49–59.
- [28] Hendriks CJ, Burton B, Fleming TR, et al. Efficacy and safety of enzyme replacement therapy with BMN 110 (elosulfase alfa) for Morquio A syndrome (mucopolysaccharidosis IVA): a phase 3 randomised placebo-controlled study. *J Inherit Metab Dis* 2014;37:979–90.
- [29] Harmatz P, Ketteridge D, Giugliani R, et al. Direct comparison of measures of endurance, mobility, and joint function during enzyme-replacement therapy of mucopolysaccharidosis VI (Maroteaux–Lamy syndrome): results after 48 weeks in a phase 2 open-label clinical study of recombinant human N-acetylgalactosamine 4-sulfatase. *Pediatrics* 2005;115:e681–9.
- [30] Decker C, Yu Z, Giugliani R, et al. Enzyme replacement therapy for mucopolysaccharidosis VI: growth and pubertal development in patients treated with recombinant human N-acetylgalactosamine 4-sulfatase. *J Pediatr Rehabil Med* 2010;3:89–100.
- [31] Braunlin E, Rosenfeld H, Kampmann C, et al. Enzyme replacement therapy for mucopolysaccharidosis VI: long-term cardiac effects of galsulfase (Naglazyme®) therapy. *J Inherit Metab Dis* 2013;36:385–94.
- [32] Moore D, Connock MJ, Wraith E, Lavery C. The prevalence of and survival in Mucopolysaccharidosis I: Hurler, Hurler–Scheie and Scheie syndromes in the UK. *Orphanet J Rare Dis* 2008;3:24.
- [33] Aldenhoven M, Wynn RF, Orchard PJ, et al. Long-term outcome of Hurler syndrome patients after hematopoietic cell transplantation: an international multicenter study. *Blood* 2015;125:2164–72.
- [34] Herskhovitz E, Young E, Rainer J, et al. Bone marrow transplantation for Maroteaux–Lamy syndrome (MPS VI): long-term follow-up. *J Inherit Metab Dis* 1999;22:50–62.
- [35] Yamada Y, Kato K, Sukegawa K, et al. Treatment of MPS VII (Sly disease) by allogeneic BMT in a female with homozygous A619V mutation. *Bone Marrow Transplant* 1998;21:629–34.
- [36] Chinen Y, Higa T, Tomatsu S, et al. Long-term therapeutic efficacy of allogeneic bone marrow transplantation in a patient with mucopolysaccharidosis IVA. *Mol Genet Metab Rep* 2014;31–41.
- [37] Prasad VK, Kurtzberg J. Transplant outcomes in mucopolysaccharidoses. *Semin Hematol* 2010;47:59–69.
- [38] Hendriks CJ, Giugliani R, Harmatz P, et al. Design, baseline characteristics, and early findings of the MPS VI (mucopolysaccharidosis VI) Clinical Surveillance Program (CSP). *J Inherit Metab Dis* 2011;36:373–84.
- [39] White KK, Karol LA, White DR, Hale S. Musculoskeletal manifestations of Sanfilippo Syndrome (mucopolysaccharidosis type III). *J Pediatr Orthop* 2011;31:594–8.
- [40] Lachman R, Martin KW, Castro S, et al. Radiologic and neuroradiologic findings in the mucopolysaccharidoses. *J Pediatr Rehabil Med* 2010;3:109–18.
- [41] Giugliani R, Herber S, de Camargo Pinto LL, Baldo G. Therapy for mucopolysaccharidosis VI: (Maroteaux–Lamy syndrome) present status and prospects. *Pediatr Endocrinol Rev* 2014;12(Suppl. 1):152–8.
- [42] Hendriks CJ, Lavery C, Coker M, et al. Burden of disease in patients with Morquio A syndrome: results from an international patient-reported outcomes survey. *Orphanet J Rare Dis* 2014;9:32.
- [43] White KK, Jester A, Bache CE, et al. Orthopedic management of the extremities in patients with Morquio A syndrome. *J Child Orthop* 2014;8:295–304.
- [44] Hendriks CJ, Berger KI, Giugliani R, et al. International guidelines for the management and treatment of Morquio A syndrome. *Am J Med Genet A* 2015;167A:11–25.
- [45] Scarpa M, Almásy Z, Beck M, et al. Mucopolysaccharidosis type II: European recommendations for the diagnosis and multidisciplinary management of a rare disease. *Orphanet J Rare Dis* 2011;6:72.
- [46] Giugliani R, Harmatz P, Wraith JE. Management guidelines for mucopolysaccharidosis VI. *Pediatrics* 2007;120:405–18.
- [47] Thawrani DP, Walker K, Polgreen LE, et al. Hip dysplasia in patients with Hurler syndrome (mucopolysaccharidosis type I H). *J Pediatr Orthop* 2013;33:635–43.
- [48] O'heareamhoin S, Bayer T, Mulhail KJ. Total hip arthroplasty in mucopolysaccharidosis type IH. *Case Rep Orthop* 2011;2011:832439.
- [49] Cimaz R, La Torre F. Mucopolysaccharidoses. *Curr Rheumatol Rep* 2014;16:389.
- [50] Montañó AM, Tomatsu S, Brusius A, et al. Growth charts for patients affected with Morquio A disease. *Am J Med Genet A* 2008;146A:1286–95.
- [51] Leighton SEJ, Papsin B, Vellodi A, et al. Disordered breathing during sleep in patients with mucopolysaccharidoses. *Int J Pediatr Otorhinolaryngol* 2001;58:127–38.
- [52] John A, Fagondes S, Schwartz I, et al. Sleep abnormalities in untreated patients with mucopolysaccharidosis type VI. *Am J Med Genet A* 2011;155A:1546–51.
- [53] Mesolella M, Cimmino M, Cantone E, et al. Management of otolaryngological manifestations in mucopolysaccharidoses: our experience. *Acta Otorhinolaryngol Ital* 2013;33:267–72.
- [54] Gönüldas B, Yilmaz T, Sivri HS, et al. Mucopolysaccharidosis: otolaryngologic findings, obstructive sleep apnea and accumulation of glucosaminoglycans in lymphatic tissue of the upper airway. *Int J Pediatr Otorhinolaryngol* 2014;78:944–9.
- [55] Keilmann A, Nakarat T, Bruce IA, et al. Hearing loss in patients with mucopolysaccharidosis II: data from HOS – the Hunter Outcome Survey. *J Inherit Metab Dis* 2012;35:343–53.
- [56] Lin HY, Shih SC, Chuang CK, et al. Assessment of hearing loss by pure-tone audiometry in patients with mucopolysaccharidoses. *Mol Genet Metab* 2014;111:533–8.
- [57] Saeed H, Nichani J, Melling C, et al. Feasibility of cochlear implantation in Mucopolysaccharidosis. *Int J Pediatr Otorhinolaryngol* 2013;77:1255–8.
- [58] Cho YS, Kim JH, Kim TW, et al. Otologic manifestations of Hunter syndrome and their relationship with speech development. *Audiol Neurotol* 2008;13:206–12.
- [59] Dangel JH. Cardiovascular changes in children with mucopolysaccharide storage diseases and related disorders – clinical and echocardiographic findings in 64 patients. *Eur J Pediatr* 1998;157:534–8.
- [60] Fesslová V, Corti P, Sersale G, et al. The natural course and the impact of therapies of cardiac involvement in the mucopolysaccharidoses. *Cardiol Young* 2009;19:170–8.
- [61] Leal GN, de Paula AC, Leone C, Kim CA. Echocardiographic study of paediatric patients with mucopolysaccharidosis. *Cardiol Young* 2010;20:254–61.
- [62] Mohan UR, Hay AA, Cleary MA, et al. Cardiovascular changes in children with mucopolysaccharide disorders. *Acta Paediatr* 2002;91:799–804.
- [63] Hendriks CJ, Al-Jawad M, Berger KI, et al. Clinical overview and treatment options for non-skeletal manifestations of mucopolysaccharidosis type IVA. *J Inherit Metab Dis* 2013;36:309–22.
- [64] Montañó AM, Lock-Hock N, Steiner RD, et al. Clinical course of sly syndrome (mucopolysaccharidosis type VII). *J Med Genet* 2016;53:403–18.
- [65] Braunlin EA, Harmatz PR, Scarpa M, et al. Cardiac disease in patients with mucopolysaccharidosis: presentation, diagnosis and management. *J Inherit Metab Dis* 2011;34:1183–97.
- [66] Kampmann C, Lampe C, Whybra-Trümpler C, et al. Mucopolysaccharidosis VI: cardiac involvement and the impact of enzyme replacement therapy. *J Inherit Metab Dis* 2014;37:269–76.
- [67] Jurecka A, Zakharova E, Cimbaliene L, et al. Mucopolysaccharidosis type VI: a predominantly cardiac phenotype associated with homozygosity for p.R152W mutation in the ARSB gene. *Am J Med Genet Part A* 2013;161A:1291–9.
- [68] Wippermann CF, Beck M, Schranz D, et al. Mitral and aortic regurgitation in 84 patients with mucopolysaccharidoses. *Eur J Pediatr* 1995;154:98–101.
- [69] Thümler A, Miebach E, Lampe C, et al. Clinical characteristics of adults with slowly progressing mucopolysaccharidosis VI: a case series. *J Inherit Metab Dis* 2012;35:1071–9.
- [70] Misumi I, Chikazawa S, Ishitsu T, et al. Atrioventricular block and diastolic dysfunction in a patient with Sanfilippo C. *Intern Med* 2010;49:2313–6.



- [71] Oudit GY, Butany J, Williams WG, et al. Left ventricular aneurysm in a patient with mucopolysaccharidosis type VI (Maroteaux-Lamy syndrome): clinical and pathological correlation. *Cardiovasc Pathol* 2007;16:237–40.
- [72] Brosius III FC, Roberts WC. Coronary artery disease in the Hurler syndrome. Qualitative and quantitative analysis of the extent of coronary narrowing at necropsy in six children. *Am J Cardiol* 1981;47:649–53.
- [73] Sohn YB, Choi EW, Kim SJ, et al. Retrospective analysis of the clinical manifestations and survival of Korean patients with mucopolysaccharidosis type II: emphasis on the cardiovascular complication and mortality cases. *Am J Med Genet A* 2012;158A:90–6.
- [74] Kampmann C, Beck M, Morin I, Loehr JP. Prevalence and characterization of cardiac involvement in Hunter syndrome. *J Pediatr* 2011;159:327–31.
- [75] Kurihara M, Kumagai K, Yagishita S. Sanfilippo syndrome type C: a clinicopathological autopsy study of a long-term survivor. *Pediatr Neurol* 1996;14:317–21.
- [76] Yasuda E, Fushimi K, Suzuki Y, et al. Pathogenesis of Morquio A syndrome: an autopsied case reveals systemic storage disorder. *Mol Genet Metab* 2013;109:301–11.
- [77] Wang RY, Covault KK, Halcrow EM, et al. Carotid intima-media thickness is increased in patients with mucopolysaccharidoses. *Mol Genet Metab* 2011;104:592–6.
- [78] Wang RY, Braunlin EA, Rudser KD, et al. Carotid intima-media thickness is increased in patients with treated mucopolysaccharidosis types I and II, and correlates with arterial stiffness. *Mol Genet Metab* 2014;111:128–32.
- [79] Kelly AS, Metzger AM, Steinberger J, Braunlin EA. Endothelial function in children and adolescents with mucopolysaccharidosis. *J Inherit Metab Dis* 2013;36:221–5.
- [80] Groothoff JW, Gruppen MP, Offringa M, et al. Increased arterial stiffness in young adults with end-stage renal disease since childhood. *J Am Soc Nephrol* 2002;13:2953–61.
- [81] Wiseman DH, Mercer J, Tylee K, et al. Management of mucopolysaccharidosis type IH (Hurler's syndrome) presenting in infancy with severe dilated cardiomyopathy: a single institution's experience. *J Inherit Metab Dis* 2013;36:263–70.
- [82] Braunlin EA, Stauffer NR, Peters CH, et al. Usefulness of bone marrow transplantation in the Hurler syndrome. *Am J Cardiol* 2003;92:882–6.
- [83] Kitabayashi K, Matsumiya G, Ichikawa H, et al. Surgical treatment for mitral stenosis in Scheie's syndrome: mucopolysaccharidosis type I-S. *Ann Thorac Surg* 2007;84:654–5.
- [84] Felice T, Murphy E, Mullen MJ, Elliott PM. Management of aortic stenosis in mucopolysaccharidosis type I. *Int J Cardiol* 2014;172:e430–1.
- [85] Van Hove JL, Wevers RA, Van Cleemput J, et al. Late-onset visceral presentation with cardiomyopathy and without neurological symptoms of adult Sanfilippo A syndrome. *Am J Med Genet A* 2003;118A:382–7.
- [86] Grinberg H, Quaio CRDAC, Avila MS, et al. The first cardiac transplant experience in a patient with mucopolysaccharidosis. *Cardiovasc Pathol* 2012;21:358–60.
- [87] Minakata K, Konishi Y, Matsumoto M, Miwa S. Surgical treatment for Scheie's syndrome (mucopolysaccharidosis type I-S). Report of two cases. *Jpn Circ J* 1998;62:700–3.
- [88] Wassman ER, Johnson K, Shapiro LJ, Itabashi H, Rimoin DL. Postmortem findings in the Hurler–Scheie syndrome (mucopolysaccharidosis I-H/S). *Birth Defects Orig Artic Ser* 1982;18:13–8.
- [89] Lin HY, Lin SP, Chuang CK, et al. Mucopolysaccharidosis I under enzyme replacement therapy with laronidase – a mortality case with autopsy report. *J Inherit Metab Dis* 2005;28:1146–8.
- [90] Solanki GA, Martin KW, Theroux MC, et al. Spinal involvement in mucopolysaccharidosis IVA (Morquio–Brailsford or Morquio A syndrome): presentation, diagnosis and management. *J Inherit Metab Dis* 2013;36:339–55.
- [91] Solanki GA, Alden TD, Burton BK, et al. A multinational, multidisciplinary consensus for the diagnosis and management of spinal cord compression among patients with mucopolysaccharidosis VI. *Mol Genet Metab* 2012;107:15–24.
- [92] Charrow J, Alden TD, Breathnach CAR, et al. Diagnostic evaluation, monitoring, and perioperative management of spinal cord compression in patients with Morquio syndrome. *Mol Genet Metab* 2015;114:11–8.
- [93] Mut M, Cila A, Varli K, Akalan N. Multilevel myelopathy in Maroteaux–Lamy syndrome and review of the literature. *Clin Neurol Neurosurg* 2005;107:230–5.
- [94] Lampe C, Lampe C, Schwarz M, et al. Craniocervical decompression in patients with mucopolysaccharidosis VI: development of a scoring system to determine indication and outcome of surgery. *J Inherit Metab Dis* 2013;36:1005–13.
- [95] Ashworth JL, Biswas S, Wraith E, Lloyd IC. Mucopolysaccharidoses and the eye. *Surv Ophthalmol* 2006;51:1–17.
- [96] Ashworth JL, Kruse FE, Bachmann B, et al. Ocular manifestations in the mucopolysaccharidoses – a review. *Clin Experiment Ophthalmol* 2010;38:12–22.
- [97] Fahnehjelm KT, Ashworth JL, Pitz S, et al. Clinical guidelines for diagnosing and managing ocular manifestations in children with mucopolysaccharidosis. *Acta Ophthalmol* 2012;90:595–602.
- [98] Summers CG, Ashworth JL. Ocular manifestations as key features for diagnosing mucopolysaccharidoses. *Rheumatology (Oxford)* 2011;50(Suppl. 5):v34–40.
- [99] Frawley G, Fuenzalida D, Donath S, et al. A retrospective audit of anesthetic techniques and complications in children with mucopolysaccharidoses. *Paediatr Anaesth* 2012;22:737–44.
- [100] Walker R, Belani KG, Braunlin EA, et al. Anaesthesia and airway management in mucopolysaccharidosis. *J Inherit Metab Dis* 2013;36:211–9.
- [101] Lin SP, Shih SC, Chuang CK, et al. Characterization of pulmonary function impairments in patients with mucopolysaccharidoses – changes with age and treatment. *Pediatr Pulmonol* 2014;49:277–84.
- [102] Walker RWM, Darowski M, Morris P, Wraith JE. Anaesthesia and mucopolysaccharidoses. A review of airway problems in children. *Anaesthesia* 1994;49:1078–84.
- [103] White K, Kim T, Neufeld JA. Clinical assessment and treatment of carpal tunnel syndrome in the mucopolysaccharidoses. *J Pediatr Rehabil Med* 2010;3:57–62.
- [104] Van Heest AE, House J, Krivit W, Walker K. Surgical treatment of carpal tunnel syndrome and trigger digits in children with mucopolysaccharide storage disorders. *J Hand Surg [Am]* 1998;23:236–43.
- [105] Rølling I, Clausen N, Nyvad B, Sindet-Pedersen S. Dental findings in three siblings with Morquio's syndrome. *Int J Paediatr Dent* 1999;9:219–24.
- [106] Neufeld EF, Muenzer J. Mucopolysaccharidoses 2001;8:3421–52.
- [107] Mylotte D, Pilote L, Ionescu-Iltu R, et al. Specialized adult congenital heart disease care: the impact of policy on mortality. *Circulation* 2014;129:1804–12.